



Case Report

Laparoscopic removal of migrated intrauterine device located on sigmoid colon, case report and literature review

Öznur Öner ^{a,†}, Aykut Özcan ^a, Zeynep Çankaya ^a^a Gynecology and Obstetrics Department, Izmir Katip Celebi University Ataturk Training and Research Hospital, Izmir, Turkey

ABSTRACT

Objective: The extrauterine migration of an intrauterine device (IUD) can be life-threatening and may require emergent surgical intervention and treatment.

Case report: A case report where an ectopic IUD located on sigmoid colon within peritoneal cavity in a 40-year-old multigravida was successfully removed by laparoscopy is described.

Conclusion: Although the practicality and success of this method depends on the position and location of the ectopic IUD and on the extent to which the device is imbedded, this case suggests that removal of the migrated IUD from the peritoneal cavity is an additional possibility for use of the laparoscope.

Keywords: Intrauterine device, Migration, Laparoscopy

ARTICLE INFO

Article history:

Received: 16 September 2019

Revision received 21 December 2019

Accepted 26 December 2019

© 2019 AEJOG.

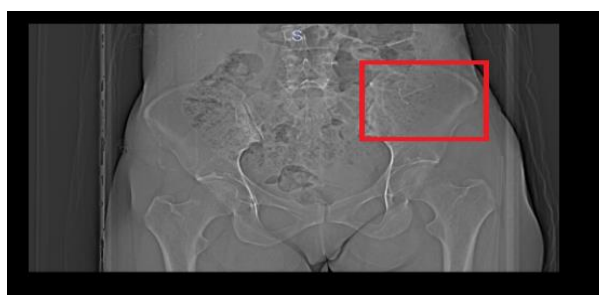
Introduction

An intrauterine contraceptive device (IUD) is a long-acting, highly effective, economic and reversible method of contraception used worldwide [1]. Currently, the most used devices are Copper IUD or Mirena (Levonorgestrel) IUD. Common complications include failed insertion, pain, vasovagal reactions, infection, menstrual abnormalities and expulsion. However, it is also associated with serious complications such as bleeding, pregnancy (intrauterine or ectopic), perforation and migration to adjacent organs or omentum [2]. Although perforation of the uterus by an IUD is not uncommon, translocation to the peritoneal cavity of this type of IUD may provoke peritoneal or omental adhesions, volvulus, uterocutaneous fistula and bowel perforation, which involves significant morbidity, and immediate surgical intervention may be required at this point [3,4]. Here, we report a case of migration of an IUD to the peritoneal cavity on sigmoid colon.

Case presentation

A 40-year-old woman presented to the emergency department with lower abdominal pain localized in the left iliac fossa for 2 months. Suprapubic and left iliac fossa areas were tender on palpation with abdominal examination. She had no medical history except a Levonorgestrel-releasing Intrauterine system (Mirena). Four months ago, an LNG-IUD was inserted to the patient due to menorrhagia, and amenorrhea developed after Mirena insertion. However, the patient's physical examination at the time of presentation revealed a lack of visualized IUD strings. Then, pelvic examination and transvaginal sonography were performed, which confirmed non-visualization of intracavitary IUD. Although the secondary amenorrhea also continued, which she thought was due to Mirena, and she denied witnessing expulsion of her IUD. Then, an abdominal X-ray was taken, which showed her IUD overlying the left iliac bone without signs of obstruction or free air (Figure 1).

Figure 1. Abdominal X-ray, IUD overlying the left iliac bone

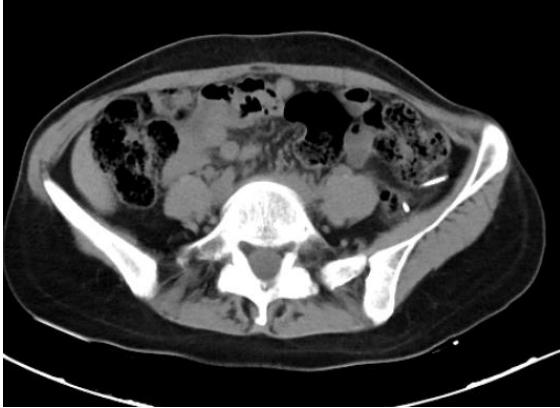

† Corresponding author.

E-mail addresses: oneroznur@hotmail.com

An abdominal computed tomography (CT) scan was performed, which localized the IUD anteriorly between the omental fat of the left lower quadrant on the left side of the peritoneal cavity and sigmoid colon (Figure 2).

Figure 2. Abdominal CT scan image



The patient was given Cefazolin-sodium and taken to the operating room for a diagnostic laparoscopy. IUD was removed from sigmoid colon with the omental fat around. The operation was successful, and the patient was discharged 1 day later with cure.

Discussion

Migration is often suspected or diagnosed when the IUD string is no longer visible at the external os. Then, transvaginal ultrasound should be performed. First, the uterus should be visualized, evaluating for a hyperechoic linear structure within the body of the uterus. If the IUD is still not seen, then abdominal radiography such as abdominal X-ray and CT can be used to localize the IUD.

The exact mechanism by which IUD perforations occur is unclear, and various etiologic theories exist. The first is that complete perforation occurs at the time the device/system is inserted, and the IUD is released beyond the serosa [5]. The second is that correct placement of the IUD occurs but is followed by transmural migration, leading to perforation. Finally, embedment may occur at the time of insertion, which predisposes to transmural migration and ultimate perforation. Other rare mechanisms have been reported, including trans-tubal migration and trans-cervical perforation.

An IUD should be inserted by specially trained health staff, and the subject should be followed up for a period of 6 weeks. Also, the subject should be informed about self-maintenance and self-control of the IUD strings 1 month after the insertion and regularly thereafter [6]. The threads may serve as important markers for the location of missing contraceptive devices. Although USG is an operator-dependent imaging technique, it can be performed in case of missing IUD strings. In addition, X-ray and/or computed tomography imaging can be used to identify the accurate location of the IUD.

CONCLUSION

In summary, the extrauterine migration of an intrauterine device (IUD) can be life-threatening and may require emergent surgical intervention and treatment. Most gynecologists have concluded that, in cases of extrauterine but intraabdominal IUD, laparoscopic removal of the IUD must be the first choice of treatment.

Disclosure

Authors have no potential conflicts of interest to disclose.

References

1. Ferguson, C. A., Costescu, D., Jamieson, M. A., & Jong, L. (2016). Transmural migration and perforation of a levonorgestrel intrauterine system: a case report and review of the literature. *Contraception*, 93(1), 81–86.
2. Bowen-Simpkins P (2004) Missing IUD fragment. *J Fam Plann Reprod Health Care* 30(4):276.
3. Stuckey A, Dutreil P, Aspuru E, Nolan TE (2005) Symptomatic cecal perforation by an intrauterine device with appendectomy removal. *Obstet Gynecol* 105(5 Pt 2):1239–1241
4. Caliskan E, Oztürk N, Dilbaz BO, Dilbaz S. Analysis of risk factors associated with uterine perforation by intrauterine devices. *Eur J Contracept Reprod Health Care*. 2003;8(3):150–155.
5. Arslan A, Kanat-Pektas M, Yesilyurt H, Bilge U. Colon penetration by a copper intrauterine device: a case report with literature review. *Arch Gynecol Obstet*. 2009;279(3):395–397. doi:10.1007/s00404-008-0716-2
6. Carmody K, Schwartz B, Chang A. Extrauterine migration of a mirena® intrauterine device: a case report. *J Emerg Med*. 2011;41(2):161–165. doi:10.1016/j.jemermed.2010.04.024

